Maxillary Tuberosity Block Bone Graft: Innovative Technique and Case Report

*Len Tolstunov, DDS**

Hard tissue defects resulting from trauma, infection, or tooth loss often lead to an unfavorable anatomy of maxillary and mandibular alveolar processes that become not suitable for implant therapy without bone grafting. The goal of pre-implant bone augmentation of the deficient alveolar ridge is reconstruction of the proper alveolar anatomy through the techniques of socket preservation, horizontal and vertical ridge augmentation, sinus bone grafting, and others. A variety of bone grafts and bone grafting materials have been used in the last 30 years for augmentation of deficient alveolar ridge for the purpose of implant treatment of partially and completely edentulous patients. Bone grafting options include autogenous, allogeneic, xenogeneic, synthetic bone, and combination of above. Autogenous bone grafts are considered "the gold standard" due to their compatibility and osteogenic potentials to form the new bone by processes of osteogenesis, osteoinduction, and osteoconduction. A particulate and block autogenous bone has been used for correction of alveolar ridge deficiency. Extraoral sites of autogenous block grafts include: ilium, calvarium, tibia, rib, and others. Intraoral sites of autogenous block grafts include symphysis and retromolar-ramus areas. In the clinical practice, a maxillary tuberosity bone graft has often been used as a particulate graft for augmentation of deficient alveolar ridge or maxillary sinus prior to or simultaneously with implant insertion. This article presents an innovative technique and reports a case of the maxillary tuberosity block bone graft that can be used to correct moderate to severe localized defects of the alveolar process prior to implant placement.

J Oral Maxillofac Surg 67:1723-1729, 2009

Maxillary tuberosity particulate graft, often in combination with a variety of bone graft substitutes, has been described in the literature and used in clinical practice as a source of autogenous bone for correction of bone deficiencies of the maxillary or mandibular alveolar ridges[1-5] and subantral augmentation (sinus lift).[6-10] It can also be used during a ridge-widening technique between cortical plates by inserting the particulate graft into the surgically created gap (split).[2] Immediate and delayed implant placement after the maxillary tuberosity particulate grafting has been described.[2,7]

The mandible is a common source of autogenous monocortical block bone grafts from the chin and ramus for mainly horizontal and sometimes vertical augmentation of the alveolar ridge defects[11-27] and occasionally for sinus floor elevation[28] in implant reconstruction cases. Mandibular tori are also described as a rare donor site for successful block grafting.[29]

On the basis of an extensive PubMed search of the published literature, no reports (to our knowledge) were found describing an intraoral block bone graft harvested from the maxillary tuberosity. In this case report, maxillary tuberosity block bone graft (MTBBG) was successfully used for correction of the alveolar ridge defect and implant reconstruction of the posterior maxilla. This new technique is described and suggested as an alternative source of intraoral autogenous block bone graft.

Report of a Case

A 59-year-old man was referred to our surgical practice for an implant consultation. His medical history was noncontributory. He was interested in replacement of his missing upper right posterior teeth, which he had lost about 5 years previously because of decay. He did not have dentures or any other treatment for missing teeth and was interested in fixed implant restorations. On examination (Figs 1, 2), the patient had a Class I malocclusion, group function on the left and cuspid disclusion on the right side, missing upper right premolars and first and second molars, mild super-eruption of opposing teeth in the lower right quadrant (second premolar and first and second molars), and otherwise stable remaining den-

*Oral and Maxillofacial Surgery, Private Practice, and Assistant Clinical Professor, Department of Oral and Maxillofacial Surgery, School of Dentistry, University of the Pacific, San Francisco, CA.

Address correspondence and reprint requests to Dr Tolstunov: Van Ness Oral Surgery & Implantology Center, 1 Daniel Burnham Ct, Suite 366 C, San Francisco, CA 94109-5460; e-mail: info@SForalsurgeon.com

0278-2391/09/6708-0023$36.00/0
doi:10.1016/j.joms.2009.03.043

FIGURE 1. Preoperative intraoral clinical photograph (occlusal view) showing edentulous right alveolar ridge of posterior maxilla.

Len Tolstunov. Maxillary Tuberosity Block Bone Graft. J Oral Maxillofac Surg 2009.

tition. The edentulous region in the upper right quadrant was analyzed for implant treatment. It had the following parameters: 28 mm of functional alveolar length along the arch, alveolar width of 6 mm in the area of both premolars and 8 mm in the area of the first and second molars, 6 mm of interocclusal height (upper alveolar ridge to the occlusal surfaces of the opposing teeth), and good attached mucosa and appropriate depth of vestibule. The patient also had a pronounced maxillary tuberosity in the same quadrant (Fig 3) extending into the vestibule with a localized exostosis, measuring about 1 cm in length and 1 cm in width. The panoramic radiograph (Fig 2) showed an adequate amount of vertical bone measuring about 12 to 13 mm below the floor of the right maxillary sinus for implant insertion. On the basis of clinical, radiographic, and model evaluations (Fig 4), it was clear that the alveolar ridge in the region of the right maxillary premolars had moderate to severe localized resorption (width deficiency) that precluded prosthetically guided implant placement in that location without the addition of bone graft.

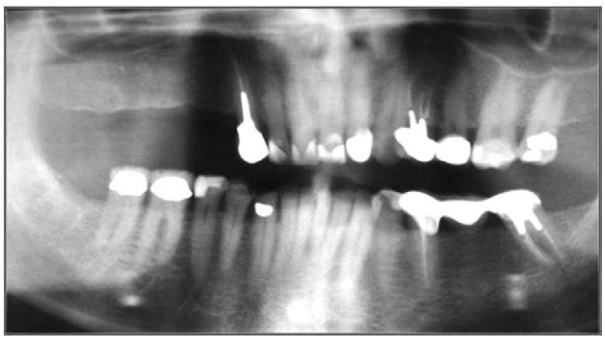

FIGURE 2. Preoperative panoramic radiograph showing edentulous right maxillary posterior region and proximity of maxillary sinus.

Len Tolstunov. Maxillary Tuberosity Block Bone Graft. J Oral Maxillofac Surg 2009.

FIGURE 3. Preoperative intraoral evaluation showing hypertrophic right maxillary tuberosity.

Len Tolstunov. Maxillary Tuberosity Block Bone Graft. J Oral Maxillofac Surg 2009.

DIAGNOSIS

The complete stomatognathic diagnosis of this patient consisted of skeletal Class I maxillomandibular relationship, Class I malocclusion, functional masticatory compromise resulting from loss of maxillary premolar and molar teeth on the right side, severe local-

FIGURE 4. Preoperative model showing significant alveolar ridge deficiency in right maxillary premolar region.

Len Tolstunov. Maxillary Tuberosity Block Bone Graft. J Oral Maxillofac Surg 2009.

ized horizontal bone deficiency of the upper right maxillary alveolar ridge in the premolar region, and hypertrophic right maxillary tuberosity.

TREATMENT PLAN

To correct the extensive 3-dimensional alveolar ridge defect, 1 of 3 commonly used techniques could potentially be chosen for this case: block bone graft, ridge-splitting or ridge-widening procedure, and distraction osteogenesis. Because of the mainly horizontal localized severe ridge deficiency, our surgical preference in this case was an intraoral block graft. The traditional intraoral sites for autogenous block graft, such as the mandibular symphysis and ramus, were considered. A large maxillary tuberosity in close proximity to the recipient site was observed. The convenience of this nontraditional donor site as a block graft led us to consider its use. A literature search did not show any information about this source of block graft or a description of the technique. After considering the advantages and disadvantages of all intraoral block grafting sites, the proximity (surgical convenience) and size (appropriate donor-recipient match) helped to finalize the donor site choice—the maxillary tuberosity. The patient's treatment plan included harvesting of the MTBBG to correct adjacent horizontal alveolar bone deficiency, followed by delayed insertion of 3 implants into the right posterior maxilla 4 to 6 months later. The patient agreed to undergo the procedure and signed the consent form. A surgical template and mounted models were ready to determine the exact position of the graft and implant sites.

OPERATIVE PHASE

The procedure was done with the patient under local anesthesia. A full-thickness mucoperiosteal flap was elevated from the canine to and behind the maxillary tuberosity. A large 1 × 1-cm exostotic maxillary tuberosity was visualized (Fig 5). An irregularity of the buccal cortical outline and alveolar ridge resorption in front of the tuberosity (premolars region) were also observed. The recipient site was prepared to receive a block graft by smoothing irregular bone, creating an appropriate mildly concave surface, and making multiple small cortical perforations for the vascular ingrowth for the graft (Fig 6). The tuberosity had an irregular shape and was slightly reduced and rounded off. A KaVo saw (KaVo Dental, Lake Zurich, IL) was used to section off the entire vestibular extension of the tuberosity in a sagittal plane. The graft measured 10 mm in width and 10 mm in length. The harvested block of bone was moved within the margins of the same wound forward and into the prepared premolar area, showed good adaptation, and was fixated with three 1.2-mm Leibinger mini screws, measuring 10 to 12 mm in length (Stryker Leibinger, Kalamazoo, MI) (Fig 7). An additional amount of particulate mixture from the same maxillary tuberosity plus 0.25 g of xenograft Bio-Oss (Osteohealth, Shirley, NY) was added around the block graft on the buccal side. A full-thickness flap was mobilized and closed primarily with No. 4 Vicryl suture (Ethicon, Somerville, NJ). The patient tolerated the procedure well and received a 1-week course of amoxicillin, Peridex mouth rinse (3M, ESPE Dental Products, St Paul, MN), and standard postoperative instructions.

Six months after surgery, the patient was re-evaluated for the implant procedure. A panoramic radio-

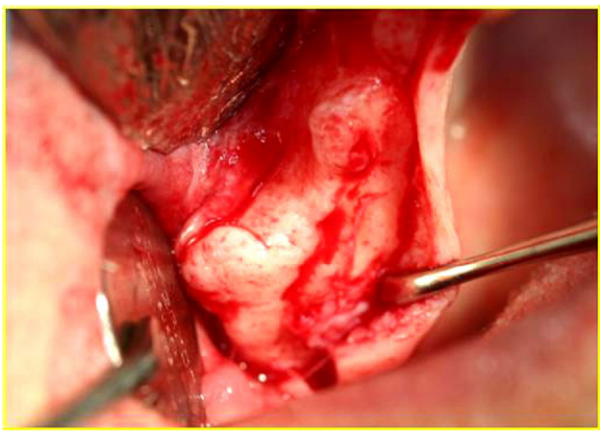

FIGURE 5. Intraoperative view of right maxillary tuberosity before its harvest (donor site).

Len Tolstunov. Maxillary Tuberosity Block Bone Graft. J Oral Maxillofac Surg 2009.

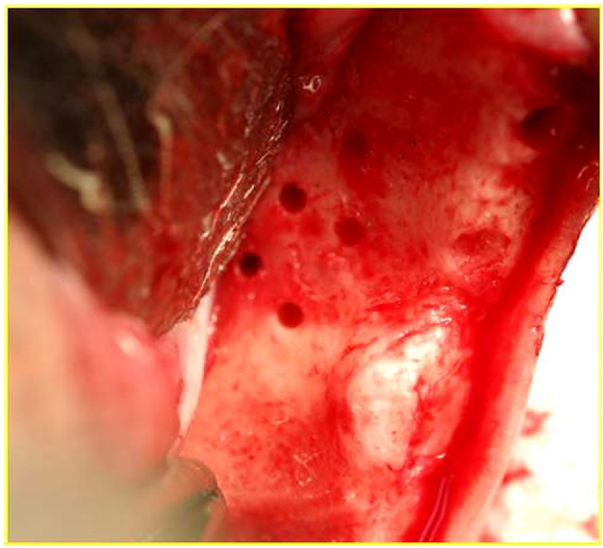

FIGURE 6. Intraoperative view of resorbed alveolar ridge. The recipient site was prepared, and multiple small cortical perforations were made for the vascular ingrowth toward the MTBBG.

Len Tolstunov. Maxillary Tuberosity Block Bone Graft. J Oral Maxillofac Surg 2009.

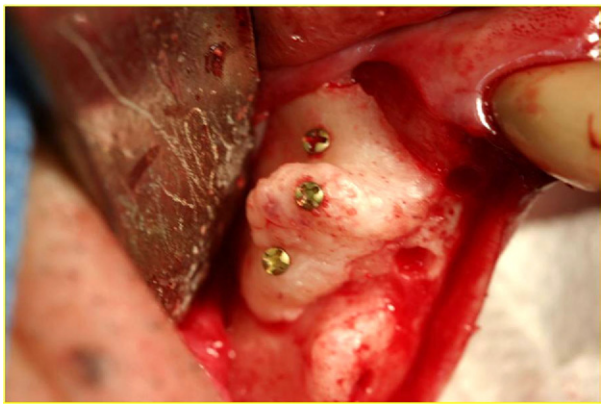

FIGURE 7. MTBBG from the right posterior maxilla was fixated to the recipient site with 3 miniscrews.

Len Tolstunov. Maxillary Tuberosity Block Bone Graft. J Oral Maxillofac Surg 2009.

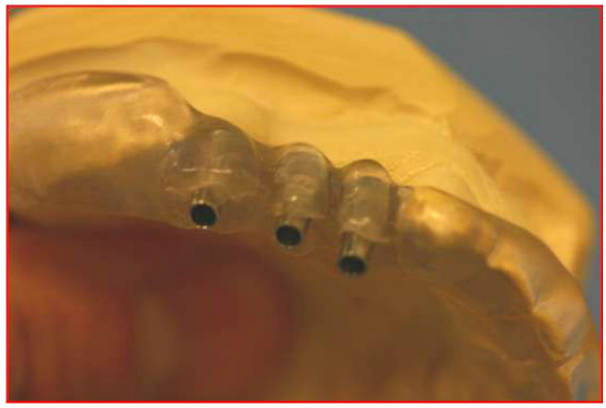

FIGURE 9. Preoperative view of surgical stent with metal inserts (cylinders) for guiding placement of 3 implants.

Len Tolstunov. Maxillary Tuberosity Block Bone Graft. J Oral Maxillofac Surg 2009.

graph was obtained, and the study models and surgical stent were prepared (Figs 8, 9). The alveolar ridge in the right posterior maxilla was measured again and had the following parameters: 28 mm of functional alveolar length along the arch, 9 mm of alveolar width along the entire alveolar ridge (2 premolars and 2 molars region), and 6 mm of interocclusal height. The patient was scheduled to undergo surgical stage 1 placement of 3 AstraTech implants (AstraTech, Waltham, MA) in the maxillary posterior region under local anesthesia. A buccal full-thickness flap was again elevated in the maxillary posterior region. An alveolar ridge of adequate width for implant placement was visualized. Intraoperative examination showed that the grafted bone looked similar to the adjacent alveolar bone with some parts of it (buccal extension) being recognizable and intact (Fig 10). A mild degree of superficial resorption of the grafted cortical bone was noticed. Three fixation (Leibinger) screws were removed, and 3 AstraTech MicroThread fixtures were placed with the aid of the surgical stent (Fig 10). To better use the functional space, implants were inserted into the position of the second molar, with 5 × 13 mm fixture; second premolar, with 5 × 11 mm fixture; and first premolar, with 4 × 15 mm fixture. Both premolar implants were placed into the solid alveolar bone augmented by MTBBG. The flap was closed with No. 4 chromic gut sutures primarily. The patient tolerated the procedure well and received a 1-week course of amoxicillin, Peridex mouth rinse, and postoperative instructions.

Surgical stage 2 placement of healing abutments (AstraTech Zebra, 4.5 mm) was done 5 months later for all 3 fixtures with a punch technique. All 3 implants were well osseointegrated. One month later, the patient was referred to his restorative dentist for

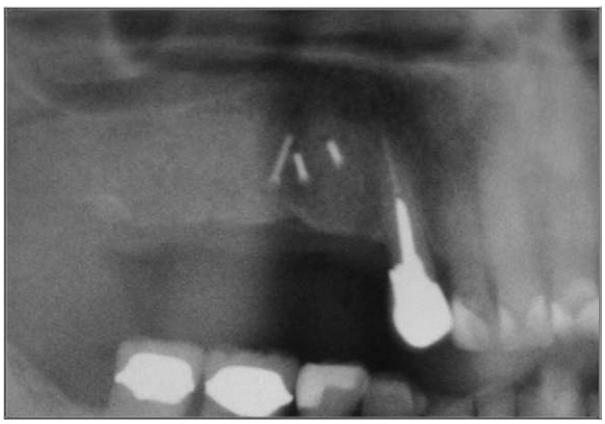

FIGURE 8. Preimplant panoramic radiograph 6 months after MTBBG. Three fixation screws can be seen. Radiographically, the grafted bone looks similar to the adjacent alveolar bone.

Len Tolstunov. Maxillary Tuberosity Block Bone Graft. J Oral Maxillofac Surg 2009.

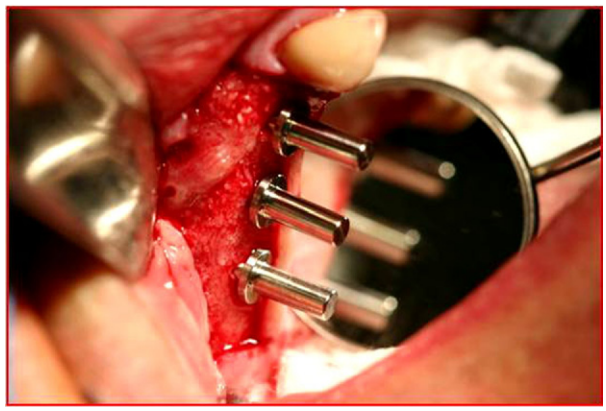

FIGURE 10. Intraoperative photograph of surgical site. Three paralleling pins were placed before insertion of 3 AstraTech implants.

Len Tolstunov. Maxillary Tuberosity Block Bone Graft. J Oral Maxillofac Surg 2009.

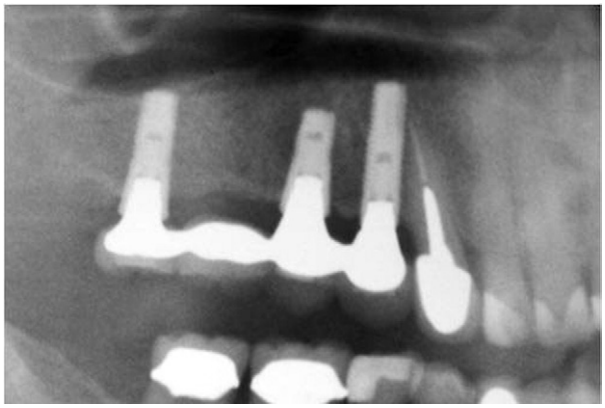

FIGURE 11. Panoramic radiograph at completion of restorative stage showing 3 implant–supported bridge in right posterior maxilla.

Len Tolstunov. Maxillary Tuberosity Block Bone Graft. J Oral Maxillofac Surg 2009.

the prosthetic stage. After completion, the patient returned to our surgical office for clinical examination and panoramic radiography (Fig 11). He underwent restoration with a 3 implant–supported 4-unit porcelain-fused-to-metal bridge; had an excellent functional, occlusal, and esthetic result (Fig 12), and was very satisfied with his treatment.

Discussion

Autogenous bone, because of its compatibility and osteogenic, osteoinductive, and osteoconductive potentials, is often preferred over xenograft, allogeneic, and synthetic bone substitutes. In a recent report, human maxillary tuberosity was considered to be a suitable source of osteoprogenitor cells for bone tissue engineering.[30] At the same time, the quality of bone in the posterior maxilla, especially in the maxillary tuberosity region, is usually substandard (type 4) and consists mainly of a thin cortical layer and a mixture of marrow spaces, adipose tissue, and a small amount of vital osteogenic cells.[1] Despite this, the maxillary tuberosity as a donor site for particulate bone is used commonly for implant-related correction of small atrophic, traumatic, and periodontal bone defects of the alveolar ridge[5] and for subantral augmentation.[7-9]

Expansion or overgrowth of the maxillary tuberosity is a very common feature that a clinician may encounter at the time of evaluation for complete maxillary denture construction in edentulous patients. It is often trimmed (excised) by surgical specialists to remove undercuts and facilitate conventional denture prosthetics. In many implant reconstruction cases involving the partial or complete arch, an enlarged maxillary tuberosity is often overlooked as a potential source of autogenous block bone graft.

Quantitative comparison of different intraoral grafts is not easy because of variability in surgical approaches. It has been reported that symphyseal (chin) block graft from the anterior mandible—which is corticocancellous in nature—can average 4 to 5 mL of volume, with a mean block size of approximately 21 × 10 × 7 mm.[25] A ramus block graft from the posterior mandible—mainly cortical in substance—can be the same size or larger depending on the particular donor site (ascending ramus, external oblique ridge, retromolar, or molar area) and the size of the alveolar deficiency that requires augmentation. The size of MTBBG—which is corticocancellous in quality—also depends on the size of the maxillary tuberosity (donor site) and the alveolar defect (recipient site). It appears that an ideal match for this type of block graft would be a horizontal (width) defect of the maxillary posterior or anterior alveolar ridge of 1 to 2 cm in length (similar to that used in our patient). The tuberosity can be shaped or reduced slightly before harvesting and can be fixated with 2 to 3 miniscrews to the prepared recipient bone. Bilaterally, enlarged maxillary tuberosities can offer a block grafting material for the larger area of localized alveolar resorption of 2 to 4 cm.

There are many advantages of using MTBBG over other intraoral sources of autogenous block grafts (symphysis, ramus). Symphyseal (chin) block grafts carry a possibility of lower incisor tooth numbness or wooden sensation, temporary or permanent mental nerve injury,[31,32] incisor tooth injury, lingual cortex fracture and perforation into the lingual soft tissue,[15] uncomfortable scarring in the lower vestibule, esthetic disharmony of the lower facial contours, and so on. Ramus block grafts bear a possibility of inferior alveolar nerve paresthesia or anesthesia, decreased sensitivity in the posterior vestibular mucosa (corre-

FIGURE 12. Intraoral clinical photograph at completion of restorative stage showing maxillary posterior porcelain-fused-to-metal 4-unit implant-supported bridge.

Len Tolstunov. Maxillary Tuberosity Block Bone Graft. J Oral Maxillofac Surg 2009.

sponding to the injury of the long buccal nerve),[31] significant postoperative discomfort, swelling, and bleeding, among other complications. Both autogenous block grafts (chin and ramus) have the inherent technical challenges of removing a block graft from the usually dense cortical bone with a saw or bur, as well as lack of postoperative complete regeneration of the donor site to the preoperative level.[32] The last drawback often requires an additional allograft or xenograft with or without a resorbable membrane to repair the newly acquired donor site defect at the time of grafting.[33] Silva et al,[34] comparing complications of intraoral donor sites for bone grafting before implant placement, reported that the major discomfort reported by patients was some degree of sensory deficit in the lower lip and mental area. Comparatively, it was found in 16% of cases after chin grafting and in 8.3% of cases after ramus grafting. No complications were found involving the maxillary tuberosity (particulate) graft.

As with any autogenous extraoral or intraoral graft, there is always an inherent possibility of postoperative graft resorption after approximately 4 to 6 months or more, if bone is not loaded with implants.[24,35] That is why a comprehensive staged treatment plan should include both phases of implant reconstruction: a preimplant phase of bone augmentation followed by an implant phase of implant insertion, eventually culminating with a restorative stage.

The medical condition of patients is also important in the selection process of patients who will benefit from this type of surgery. Intraoral bone block grafts may not be an ideal option for (uncontrolled) diabetic patients and (heavy) smokers.[19]

The maxillary tuberosity is often overlooked during implant evaluation as a potential candidate for not only particulate but also block bone grafts for localized defects of the alveolar ridge. A clinical examination of the maxillary tuberosity region should be part of the routine evaluation of patients when an intraoral block bone graft is contemplated. Modern cone beam CT scan (in addition to panoramic imaging) can offer detailed anatomy of the maxilla and mandible that can help to make a 3-dimensional preoperative assessment of the best source of block graft.

It seems that the use of the maxillary tuberosity, if large enough and suitable for a block graft, can be a relatively simple and valuable alternative technique that can offer an intraoral corticocancellous autogenous graft with fewer intraoperative difficulties and postoperative complications, no need to repair the donor site, and excellent potential to correct localized alveolar ridge defects. It is also a source of both block and particulate autogenous bone.

Further research comparing different intraoral sites of block bone grafting for implant treatment can help to evaluate the advantages and disadvantages of one graft over another.

Acknowledgment

All surgeries were done by Len Tolstunov, DDS. The restorative treatment was done by Khosrow Sigaroudi, DDS, and John Jaber, DDS.

References

1. Gapski R, Satheesh K, Cobb CM: Histomorphometric analysis of bone density in the maxillary tuberosity of cadavers: A pilot study. J Periodontol 77:1085, 2006
2. Guirado JL, Yuguero MR, Carrion Del Valle MJ, et al: A maxillary ridge splitting technique followed by immediate placement of implants: A case report. Implant Dent 14:14, 2005
3. Simion M, Fontana F: Autogenous and xenogeneic bone grafts for the bone regeneration. A literature review. Minerva Stomatol 53:191, 2004
4. Moenning JE, Graham LL: Elimination of mandibular labial undercut with autogenous bone graft from a maxillary tuberosity. J Prosthet Dent 56:211, 1986
5. ten Bruggenkate CM, Kraaijenhagen HA, van der Kwast WA, et al: Autogenous maxillary bone grafts in conjunction with placement of I.T.I. endosseous implants. A preliminary report. Int J Oral Maxillofac Surg 21:81, 1992
6. Pacifici L, Casella F, Ripari M: Lifting of the maxillary sinus: Complementary use of platelet rich plasma, autologous bone deproteinised bovine bone. Minerva Stomatol 52:471, 2003
7. Raghoebar GM, Timmenga MN, Reintsema H, et al: Maxillary bone grafting for insertion of endosseous implants: Results after 12-124 months. Clin Oral Implants Res 12:279, 2001
8. Raghoebar GM, Batenburg RH, Vissink A, et al: Augmentation of localized defects of the anterior maxillary ridge with autogenous bone before insertion of implants. J Oral Maxillofac Surg 54:1180, 1996
9. Raghoebar GM, Brouwer TJ, Reintsema H, et al: Augmentation of the maxillary sinus floor with autogenous bone for the placement of endosseous implants: A preliminary study. J Oral Maxillofac Surg 51:1198, 1993
10. Yildirim M, Spiekermann H, Handt S, et al: Maxillary sinus augmentation with the xenograft Bio-Oss and autogenous intraoral bone for qualitative improvement of the implant site: A histologic and histomorphometric clinical study in humans. Int J Oral Maxillofac Implants 16:23, 2001
11. von Ark T, Buser D: Horizontal ridge augmentation using autogenous block grafts and the guided bone regeneration technique with collagen membranes: A clinical study with 42 patients. Clin Oral Implants Res 17:359, 2006
12. Pikos MA: Block autografts for localized ridge augmentation: Part I. The posterior maxilla. Implant Dent 8:279, 1999
13. Pikos MA: Block autografts for localized ridge augmentation: Part II. The posterior mandible. Implant Dent 9:67, 2000
14. Proussaefs P, Lozada J, Kleinman A, et al: The use of ramus autogenous block grafts for vertical alveolar ridge augmentation and implant placement: A pilot study. J Oral Maxillofac Implants 17:238, 2002
15. Cordaro L, Amade DS, Cordaro M: Clinical results of alveolar ridge augmentation with mandibular block bone grafts in partially edentulous patients prior to implant placement. Clin Oral Implants Res 13:103, 2002
16. Lee CY: Immediate load protocol for anterior maxilla with cortical bone from mandibular ramus. Implant Dent 15:153, 2006
17. Sethi A, Kaus T: Ridge augmentation using mandibular block bone grafts: Preliminary results of an ongoing prospective study. Int J Oral Maxillofac Implants 16:378, 2001
18. Schwartz-Arad D, Levin L: Multitier technique for bone augmentation using intraoral autogenous bone blocks. Implant Dent 16:5, 2007

19. Schwartz-Arad D, Levin L, Sigal L: Surgical success of intraoral autogenous block onlay bone grafting for alveolar ridge augmentation. Implant Dent 14:131, 2005
20. Schwartz-Arad D, Levin L: Intraoral autogenous block onlay bone grafting for extensive reconstruction of atrophic maxillary alveolar ridges. J Periodontol 76:636, 2005
21. Levin L, Nitzan D, Schwartz-Arad D: Success of dental implants placed in intraoral block bone grafts. J Periodontol 78:18, 2007
22. Hwang KG, Shim KS, Yang SM, et al: Partial-thickness cortical bone graft from the mandibular ramus: A non invasive harvesting technique. J Periodontol 79:941, 2008
23. Cordaro L, Rossini C, Mijiritsky E: Fracture and displacement of lingual cortical plate of mandibular symphysis following bone harvesting: Case report. Implant Dent 13:202, 2004
24. Urbani G, Lombardo G, Santi E, et al: Localized ridge augmentation with chin grafts and resorbable pins: Case reports. Int J Periodontics Restorative Dent 18:363, 1998
25. Montazam A, Valauri DV, St-Hilaire H, et al: The mandibular symphysis as a donor site in maxillofacial bone grafting: A quantitative anatomic study. J Oral Maxillofac Surg 58:1368, 2000
26. Garg AK, Morales MJ, Navarro I, et al: Autogenous mandibular bone grafts in the treatment of the resorbed maxillary anterior alveolar ridge: Rationale and approach. Implant Dent 7:169, 1998
27. Misch CM, Misch CE: The repair of localized bone ridge defects for implant placement using mandibular bone grafts. Implant Dent 4:261, 1995
28. Khoury F: Augmentation of the sinus floor with mandibular bone block and simultaneous implantation: A 6 year clinical investigation. Int J Oral Maxillofac Implants 14:557, 1999
29. Proussaefs P: Clinical and histologic evaluation of the use of mandibular tori as donor site for mandibular block grafts: Report of three cases. Int J Periodontics Restorative Dent 26:43, 2006
30. Cicconetti A, Sacchetti B, Bartoli A, et al: Human maxillary tuberosity and jaw periosteum as sources of cells for tissue engineering. Oral Surg Oral Med Oral Pathol Oral Radiol Endod 104:618, 2007
31. Clavero J, Lundgren S: Ramus or chin grafts for maxillary sinus inlay and local onlay augmentation: Comparison of donor site morbidity and complications. Clin Implant Dent Relat Res 5:154, 2003
32. Weibull L, Widmark G, Ivanoff CJ, et al: Morbidity after chin bone harvesting—A retrospective long-term follow-up study. Clin Implant Dent Relat Res Jul 23 2008 [Epub ahead of print]
33. Miller NA, Penaud J, Kohler C, et al: Regeneration of bone graft donor sites. Clin Oral Implants Res 10:326, 1999
34. Silva FM, Cortez AL, Moreira RW, et al: Complications of intraoral donor site for bone grafting prior to implant placement. Implant Dent 15:420, 2006
35. Araujo MG, Sonohara M, Hayacibara R, et al: Lateral ridge augmentation by the use of grafts comprised of autologous bone or a biomaterial. An experiment in the dog. J Clin Periodontol 29:1122, 2002